Managing Airway Obstruction in Robin Sequence with Concomitant Multi-level Airway Disease

Acara Turner BS, Amjed Abu-Ghname MD, Matthew J. Davis BS, Leslie W. Davies PA-C, Mohamad Masoumy MD, Deepak K. Mehta MD, Jeffrey S. Heinle MD, Edward P. Buchanan MD

Texas Children's Hospital, Division of Plastic and Reconstructive Surgery, Baylor College of Medicine

Background

- Pierre Robin sequence (PRS) is a triad of micrognathia, glossoptosis, and tongue-based airway obstruction (TBAO).
- Airway compromise in PRS leads to increased work of breathing, feeding difficulties, and failure to thrive, with an estimated mortality rate of 3% to 65%.
- While the gold standard to relieve the airways has been tracheostomy, additional modalities exist that avoid the morbidity, high cost, and occasional mortality associated with tracheostomy.

Project Aim: Our goal is to describe the second reported case of PRS with concomitant complete tracheal rings and highlight the importance of collaborative efforts to avoid tracheostomy.

Case Presentation

- At birth, the patient was noted to have micrognathia and cleft palate.
- Postnatally, the patient developed respiratory distress and subsequently required intubation.
- One hour after successful intubation, the endotracheal tube became dislodged and the patient decompensated, requiring subsequent transfer to our institution.
- He was found to have glossoptosis, micrognathia, and a Veau II cleft palate.
- Dynamic CT imaging demonstrated complete cartilaginous tracheal rings inferior to the cricoid.

Case Presentation

Airway Management

- The patient underwent a two-staged approach encompassing a slide tracheoplasty to repair tracheal stenosis followed by mandibular distraction osteogenesis to correct the mandible.
- Multidisciplinary team: Plastic Surgery, Cardiothoracic Surgery, ENT, Anesthesiology, Pulmonology, Medicine, Critical Care

Operation I
- Median sternotomy, cardiopulmonary bypass.
- Slide tracheoplasty

Operation II
- Placement of mandibular distractors.
- Oral ETT exchanged for nasal ETT.

Operation III
- Direct laryngoscopy and bronchoscopy.
- Removal of distractor arms.

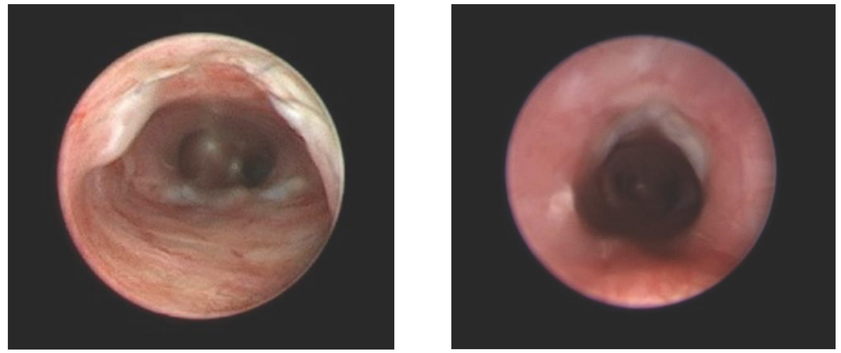

Figure 1. Direct laryngoscopy and bronchoscopy evaluation. Photodocumentation of a well-healed tracheoplasty site, 7 days after the procedure.

Postoperative Management

- On post-operative day 39, the patient developed respiratory distress.
- Upon transitioning to CPAP, he had worsening of symptoms with apnea and desaturation requiring endotracheal intubation.
- Bronchoscopy and CT imaging showed no evidence of airway anomalies or tracheobronchomalacia.
- The patient slowly improved with conservative management and is breathing room air.

Discussion

- Management of airway obstruction in Pierre Robin Sequence ranges from prone positioning and supplemental oxygen to tracheostomy or distraction osteogenesis.
- In patients with complex medical conditions, airway compromise requires extensive operative planning by a multidisciplinary team. While tracheostomy has a role in some cases, more novel approaches are necessary to avoid the consequences of a tracheostomy.
- Congenital tracheal stenosis is rare and difficult to manage. Treatment has evolved over the past two decades with sliding tracheoplasty being the gold standard for treatment.
- Our patient's management included a sliding tracheoplasty and mandibular distraction, a novel approach to correction of airway obstruction in PRS.

Conclusion

- This is the 2nd documented case of PRS with concomitant complete tracheal rings.
- In the setting of multi-level airway disease where mandibular distraction is typically contraindicated, identification of treatable airway anomalies and a multidisciplinary approach is warranted.
- Managing complex airway pathology with a collaborative team leads to better long-term results and provide the field with an alternative paradigm.