Gross Motor Delay in a Toddler Following Vegan Diet: Case of Severe Vitamin D Deficiency

Anna Cymbaluk, MD

David Paul, MD

Texas Children's Hospital

Baylor College of Medicine

Texas Children's Hospital, Department of Pediatrics, Diabetes and Endocrinology, Baylor College of Medicine

BACKGROUND

The true prevalence for Vitamin D deficiency rickets in North America is unknown, given that recent publications are largely case reports or case series. Patients with rickets may have no presenting symptoms or can present with varying degrees of irritability and bone pain, gross motor developmental delay, long bone bowing, and poor appetite, growth, and weight gain.

PURPOSE

Describe unique features of a common diagnosis, vitamin D deficiency.

METHODS

23 month old unimmunized male who presented with a three day history of fever, tachypnea, and worsening irritability, found to be hypocalcemic to 4.0 mg/dL, with Vitamin D deficiency [25-OH Vitamin D level 8.0 ng/mL levels >20 ng/mL considered sufficient in childhood], and appropriate PTH elevation to 162.5 pg/mL. Patient was breastfed and following vegan diet, along with parents. Patient noted to be gross motor delayed [not yet walking] with short stature [length Z score -4.02] and lack of primary teeth eruption; See figure 1. Admission exam notable for frontal bossing, bowing of legs, and widened wrists. EKG revealed prolonged QTC interval.

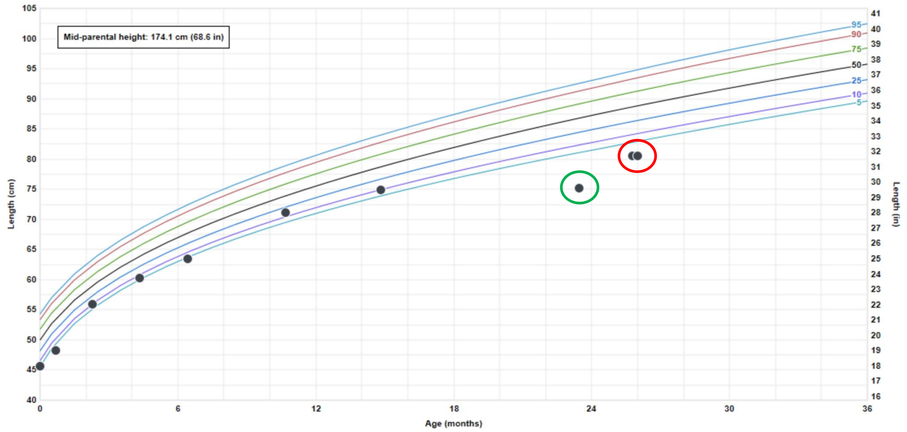

Fig 1: Length growth chart, from 0-36 months; Point circled in green is upon admission; Points circled in red are at outpatient follow up.

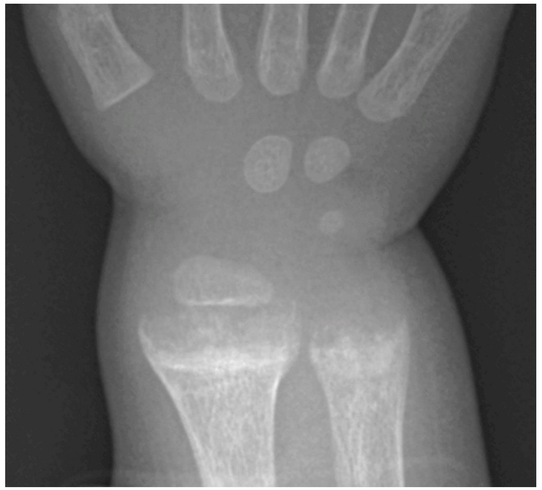

Fig 2: Metaphyseal cupping and fraying involving radius and ulna.

Fig 3: Improvement of metaphyseal cupping, 4 weeks into treatment.

RESULTS

Patient required calcium continuous intravenous infusion in addition to oral supplementation of both calcium and vitamin D. QTC interval normalized with improved calcium level. Genetic skeletal survey revealed diffuse metaphyseal cupping, irregularity, and widening involving long bones at ankles, knees, and wrists with mild diffuse osteopenia, consistent with rickets; See figure 2. Patient was discharged home on ~160 mg/kg/day of elemental calcium, as well as Vitamin D3 weekly for 6 weeks. At first follow up visit 2 weeks after admission, patient was walking with overall improved activity. After total Vitamin D supplementation of 300,000 units, patient transitioned to 1000 IU D2 daily, given vegan diet. Follow up x-ray of wrist revealed improving rickets, see figure 3.

CONCLUSION

Pediatricians should consider Vitamin D deficiency in patients with gross motor delay, particularly in those following low-vitamin D diets, such as veganism. In patients following vegan diets, supplement with Vitamin D2, as it is plant derived [UVB radiated fungi] as opposed to Vitamin D3 [UVB radiated sheep skin lanolin]. This is an entirely preventable disease.

REFERENCES

1. Misra, et al. Vitamin D deficiency in children and its management: review of current knowledge and recommendations. *Pediatrics* 2008;122:398–417.
2. Antonucci, et al. Vitamin d deficiency in childhood: old lessons and current challenges. J Pediatr Endocrinol Metab 2018; 31(3): 247–260.
3. Tripkovic, et al. Comparison of vitamin d2 and vitamin d3 supplementation in raising serum 25-hydroxyvitamin D status: a systemic review and meta-analysis. American Journal of Clinical Nutrition. 2012 June; 95(6):1357-1364.